Zoonosis Update

Ehrlichiosis and related infections

Jennifer H. McQuiston, DVM, MS; Candace L. McCall, DVM, MPH; William L. Nicholson, PhD

The term ehrlichiosis has been broadly applied to a variety of diseases of humans and animals caused by pathogens formerly classified in the genus *Ehrlichia*. However, a recently proposed taxonomic reorganization[1] has recommended the reclassifications of some former *Ehrlichia* species under the genera *Anaplasma* and *Neorickettsia* and *Cowdria ruminantium* under the genus *Ehrlichia*.[1] Therefore, the term ehrlichiosis is no longer accurately descriptive of the nature of infections caused by these diverse pathogens, but usage of the term persists, and it will be used here for simplicity.

The purpose of this review is to summarize pertinent points regarding a few of these pathogens that may infect both humans and animals and are of zoonotic importance in the United States, specifically *Anaplasma phagocytophilum* (formerly *Ehrlichia phagocytophila)*, *E chaffeensis*, *E ewingii*, and *E canis* (**Table 1**). Several related pathogens will not be discussed in this review; although *E sennetsu* causes infections in humans, this pathogen is not found in the United States, and additional pathogens of veterinary interest in the United States such as *Neorickettsia risticii* (formerly *E risticii*, the agent of Potomac horse fever or equine monocytic ehrlichiosis), *E platys* (the agent of canine cyclic thrombocytopenia), and *E bovis* are not known to cause infections in humans.

Pathogen Characteristics

Ehrlichia and *Anaplasma* species belong to the family Anaplasmataceae.[1] These organisms are small (0.5- to 1.5-µm), gram-negative, pleomorphic, obligate intracellular bacteria that reside and replicate in membrane-bound vacuoles of eukaryotic cells.[2] *Anaplasma phagocytophilum, E chaffeensis, E ewingii*, and *E canis* primarily invade mammalian leukocytes, in which they multiply and form membrane-bound, intracytoplasmic colonies called morulae.[2] The diseases caused by these pathogens have traditionally been categorized by the type of blood cell most commonly infected. For example, *E chaffeensis* and *E canis* reside primarily in monocytes, and the disease caused by these agents is frequently called monocytic (or monocytotropic) ehrlichiosis. *Anaplasma phagocytophilum* and *E ewingii* reside primarily in granulocytes, and the disease caused by these agents is often referred to as granulocytic (or granulocytotropic) ehrlichiosis. However, some *Ehrlichia* and *Anaplasma* species have been found in cells other than their chief target cell type. In addition, more than 1 genus or species may be responsible for monocytic or granulocytic ehrlichiosis. Thus, the traditional cell-based classification scheme is not adequately descriptive of these diseases.

The *Ehrlichia* and *Anaplasma* species discussed in this review are zoonotic tick-borne pathogens. These agents are maintained in wildlife hosts and are transmitted between animals through the bites of infected ticks. Humans and domestic animals such as dogs are thought to be largely accidental hosts and are unlikely to play an important role in the natural maintenance cycle of these pathogens. White-tailed deer are important reservoirs for both *E chaffeensis* and *E ewingii*.[3,4] Red foxes (*Vulpes vulpes*) have been shown to be competent hosts for *E chaffeensis* through experimental infection.[5] Antibodies against *E chaffeensis* have also been detected in raccoons (*Procyon lotor*) and opossums (*Didelphis virginianus*),[6,7] although a role for these species in the natural maintenance cycle of *E chaffeensis* has not been well established. *Ehrlichia chaffeensis* and *E ewingii* are transmitted among reservoir species and to accidental hosts such as humans and dogs by the lone star tick (*Amblyomma americanum*; **Fig 1**),[8,9] which is distributed throughout the southeastern and south-central United States.

In the eastern United States, *A phagocytophilum* is maintained in white-tailed deer and the white-footed mouse (*Peromyscus leucopus*; **Fig 2**).[10-12] Transmission to humans occurs through the bite of the black-legged tick (*Ixodes scapularis*),[13] which is the tick vector that is also capable of transmitting *Borrelia burgdorferi* (the causative agent of Lyme borreliosis) and *Babesia microti* (the causative agent of babesiosis). In the western United States, *A phagocytophilum* is likely maintained in rodents such as woodrats (*Neotoma* spp; **Fig 3**) and in cervids, including mule deer (*Odocoileus hemionus hemionus*), black-tailed deer (*O hemionus columbianus*), and elk (*Cervus elaphus*).[11,14-16] Evidence of exposure to *A phagocytophilum* has also been found in black bears (*Ursus americanus*), mountain lions (*Puma concolor*), and coyotes (*Canis latrans*), although the role of these animals as reservoirs is undefined.[17-19] The tick vector responsible for transmission of *A phagocytophilum*

From the Centers for Disease Control and Prevention, National Center for Infectious Diseases, Division of Viral and Rickettsial Diseases, Viral and Rickettsial Zoonoses Branch, 1600 Clifton Rd, Mailstop G-13, Atlanta, GA 30333 (McQuiston, Nicholson); and the United States Air Force, Biomedical Sciences Corps, Department of Defense, 1607 Porter St, Ft Detrick, MD 21702 (McCall).

The views expressed in this article are those of the authors and do not reflect the official policy or position of the Department of Defense or the US Government.

Address correspondence to Dr. McQuiston.

Table 1—Characteristics of pathogens that cause ehrlichiosis in the United States

Pathogen	Affected species*	Tick vectors in the United States	Disease
Ehrlichia canis	Dogs	*Rhipicephalus sanguineus*	Canine ehrlichiosis
	Humans	Tick vector unknown	Rare, no disease
E chaffeensis	Humans	*Amblyomma americanum*	Human monocytic ehrlichiosis
	Dogs	*A americanum*	Unnamed
	Goats	*A americanum*	Unnamed
E ewingii	Humans	*A americanum*	Human ehrlichiosis
	Dogs	*A americanum*	Canine granulocytic ehrlichiosis
Anaplasma phagocytophilum	Humans	*Ixodes* spp	Human granulocytic ehrlichiosis
	Horses	*Ixodes* spp	Equine ehrlichiosis
	Ruminants	*Ixodes* spp	Tick-borne fever (not yet recognized in the United States)

*Humans and domestic species only.

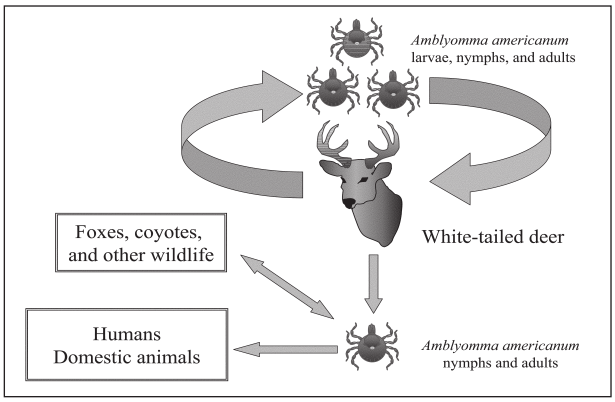

Figure 1—Pathway of natural transmission for *Ehrlichia chaffeensis* and *E ewingii*.

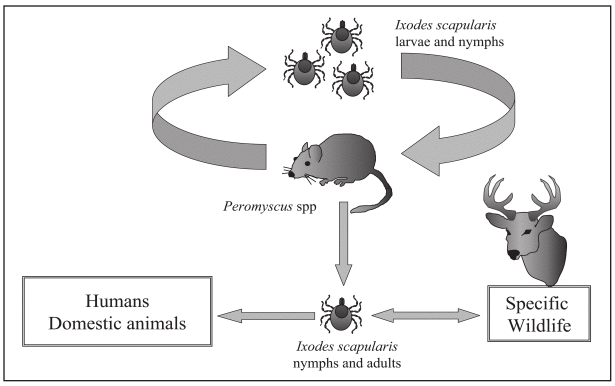

Figure 2—Pathway of natural transmission for *Anaplasma phagocytophilum* in the eastern United States.

among woodrats is *I spinipalpis*, which is a species of tick that does not feed on humans.[20] The primary vector responsible for transmission of *A phagocytophilum* from the wildlife reservoir to humans and domestic animals in the western United States is the western blacklegged tick (*I pacificus*).[21,22]

The tick vectors responsible for transmission of *E chaffeensis*, *E ewingii*, and *A phagocytophilum* are members of the family Ixodidae (also known as hard ticks).[23] These ticks have 4 distinct stages in their life cycles: egg, larva, nymph, and adult.[23] A blood meal

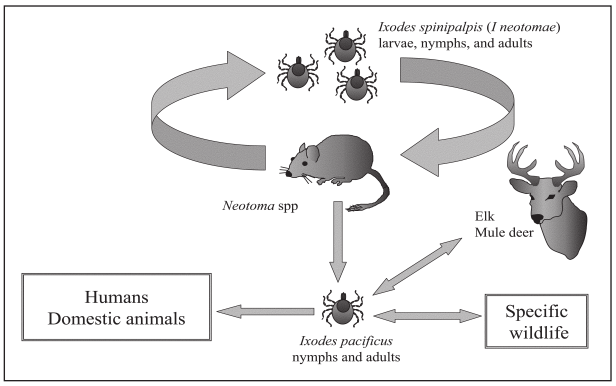

Figure 3—Pathway of natural transmission for *A phagocytophilum* in the western United States.

is required for transition from larva to nymph and from nymph to adult[23]; adult ticks also take a blood meal to complete the life cycle. Transovarial transmission of the bacteria from an adult tick to eggs is not believed to occur. Therefore, immature ticks (larvae and nymphs) must feed on infected animals to acquire and transmit infection to the successive life stages (nymphs and adults, respectively). This phenomenon is known as trans-stadial transmission.[12,13] Most ehrlichial infections are reported in the spring and summer and coincide with peak densities of vector tick populations.[24-26]

Tick transmission is believed to be the only epidemiologically important means of acquiring infection. Exposure to deer blood has been suggested as a possible means of transmission of *A phagocytophilum*, but firm evidence is lacking.[27,28] Direct infection from dogs to humans has not been identified.[29] There is experimental evidence to support blood transfusion as a means of transmission of *E phagocytophilum*, and a single case of human infection via this mechanism has been reported.[30] In addition, perinatal transmission of *A phagocytophilum* in humans has been reported.[31] However, these routes of transmission are rare; at present, human blood products are not routinely screened for evidence of infection prior to use.[30]

Ehrlichiosis in Humans

In the United States, the most commonly reported pathogens causing ehrlichiosis in humans are *E chaffeensis* and *A phagocytophilum*. *Ehrlichia chaffeensis* causes a monocytic form of illness that is often referred to as **human monocytic ehrlichiosis (HME)**, and *A phagocytophilum* causes a granulocytic form of disease known as **human granulocytic ehrlichiosis (HGE)**.[32] The strain of *A phagocytophilum* that infects humans in the United States is closely related to strains of *A phagocytophilum* isolated from horses in the United States and ruminants in Europe.[1] In addition, several cases of granulocytic ehrlichiosis have been attributed to *E ewingii* in the central United States.[33]

Results of serologic studies[34-36] indicate widespread prevalence of antibodies against *E chaffeensis* among persons living in the southeastern and south-central United States and against *A phagocytophilum* in inhabitants of the northeastern and western United States. Data from a serologic study[34] involving children living in several southeastern and south-central states indicated a seroprevalence for *E chaffeensis* of 13% (titers ≥ 1:80). Results of surveys of healthy adults from New York state and Wisconsin indicate seroprevalence for *A phagocytophilum* of 3% and 15%, respectively.[35,36] Over 1,200 cases of ehrlichiosis were reported to state health departments in the United States from 1986 to 1997 **(Fig 4)**.[32] Most cases of HME were reported from the southeastern and south-central United States **(Fig 5)**, whereas HGE was reported mainly from the northeast and west-coast regions **(Fig 6)**. Human ehrlichiosis was made a nationally reportable disease by the Council of State and Territorial Epidemiologists in 1998, and state health departments are encouraged to report cases of human ehrlichiosis to the **Centers for Disease Control and Prevention (CDC)**. From 1999 through 2001, the mean numbers of cases of HME and HGE that were reported to CDC were 81 and 190, respectively.[37-39] However, because of the protean nature of clinical signs and the need for laboratory confirmation of infection, the disease is probably under-recognized and underreported.

Following a bite from an infected tick, the incubation period for ehrlichiosis in humans is typically 1 week (range, 1 to 21 days).[26,40] *Ehrlichia chaffeensis* and *A phagocytophilum* cause clinically similar illnesses; affected individuals may be asymptomatic or have signs of disease that range from mild to severe. Of the reported cases, 2% to 3% have resulted in death.[26,33,41] Early signs include fever, headache, malaise, and muscle aches. Other signs and symptoms may include nausea, vomiting, diarrhea, cough, joint pain, and mental confusion.[26,33,41] A rash develops in > 33% of patients with HME (commonly in younger patients), but is rarely reported with HGE.[26,41] Common hematologic and serum biochemical abnormalities include thrombocytopenia and high liver enzyme activities.[26,33,41] Ehrlichiosis can progress to severe illness and may include prolonged fever, renal failure, disseminated intravascular coagulopathy, meningoencephalitis, adult respiratory distress syndrome, seizures, or coma.[26,33,41] A protracted syndrome characterized by recurrent fever, chills, and fatigue has been reported after infection with *A phagocytophilum*.[42] To date, there have been few reports of infection with *E ewingii*, but clinical signs appear similar to those associated with other forms of ehrlichiosis. Immunocompromised individuals, such as organ transplant recipients and persons with human immunodeficiency virus infection, may be at increased risk for development of clin-

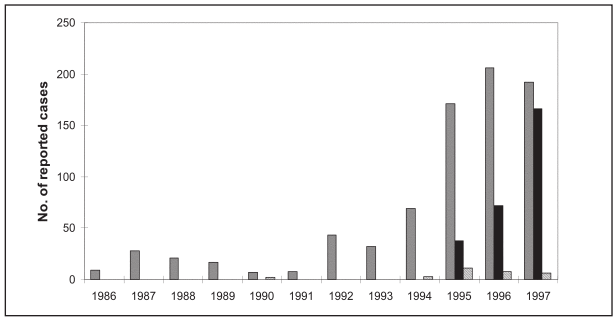

Figure 4—Number of cases of ehrlichiosis caused by *E chaffeensis* (resulting in human monocytic ehrlichiosis [HME]; gray bar), *A phagocytophilum* (resulting in human granulocytic ehrlichiosis [HGE]; black bar), and unspecified ehrlichial agents (hatched bar) reported to state health departments in the United States, 1986 through 1997.[32]

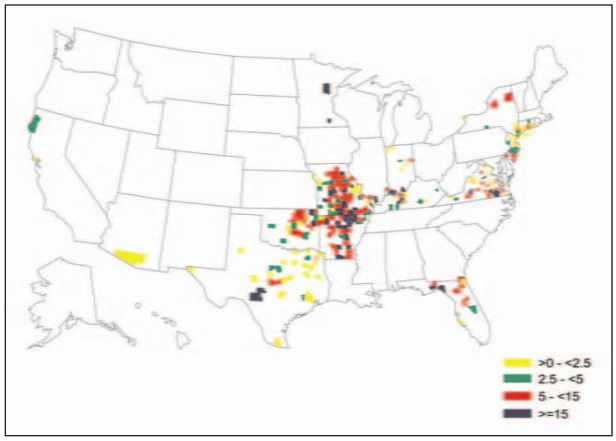

Figure 5—Mean annual incidence of HME (cases reported to the Centers for Disease Control by state health departments per million persons) in the United States by county, 1986 through 1997.[32]

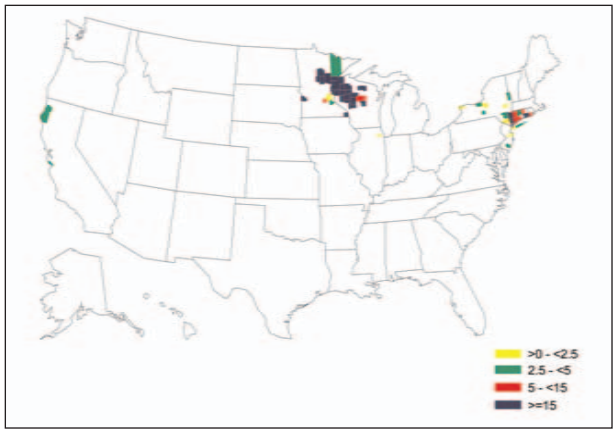

Figure 6—Mean annual incidence of HGE (cases reported to the Centers for Disease Control by state health departments per million persons) in the United States by county, 1986 through 1997.[32]

ical signs of ehrlichiosis after exposure to the causative agents.[33,43,44]

Ehrlichiosis in Animals

Dogs—In 1935, *E canis* infection was recognized as a disease of dogs by veterinarians working at the Pasteur Institute in Algeria.[45] The disease gained attention during the Vietnam conflict in the late 1960s because > 200 dogs belonging to the US military forces died as a result of an epizootic of highly fatal hemorrhagic disease known as tropical canine pancytopenia.[46] Development of the disease was associated with heavy infestations of *Rhipicephalus sanguineus* (the brown dog tick), which is the primary vector of *E canis*.[47] The age, breed, and immune competence of dogs are believed to influence the severity of infection, and some affected dogs may not have clinical signs of illness.[48] Ehrlichiosis in dogs has 3 distinct phases. During the acute phase, which generally lasts 1 to 3 weeks, dogs have nonspecific signs; these include fever, anorexia, weight loss, signs of depression, splenomegaly, and lymphadenopathy.[48-51] Anemia and thrombocytopenia may be detected.[49] If affected dogs are not treated, a subclinical phase develops in which dogs appear to return to normal but remain seropositive; mild thrombocytopenia may be detected.[52] In certain dogs, chronic infection may develop, which can be severe and life threatening in immunocompromised dogs or certain breeds (eg, German Shepherd).[51] In the severe form of disease, marked weight loss and emaciation, lymphadenopathy, pyrexia, and hemorrhagic disease are commonly observed.[50,53] Severe pancytopenia with nonregenerative anemia may also be detected; death results from extensive hemorrhage or secondary infection.[53] To the authors' knowledge, only 1 documented case of human infection with *E canis* has been reported in the medical literature. *Ehrlichia canis* was isolated from the blood of a healthy adult in Venezuela who reported close contact with an *E canis*-infected dog.[54] Although morulae were observed on cytologic examination of a blood smear from this individual, the infection did not result in clinical signs.

In addition to infection with *E canis*, a granulocytic form of ehrlichiosis has been observed in dogs infected with *E ewingii* and *A phagocytophilum*.[55-58] Common clinical signs associated with these infections include fever, lethargy, lymphopenia, and thrombocytopenia.[56] Results of a study[57] of clinically normal dogs from California indicated a seroprevalence for *A phagocytophilum* of 8.7%.[57] *Ehrlichia chaffeensis* infection has also been detected in dogs,[58] and coinfection with multiple ehrlichial pathogens has been reported.[59,60]

Horses—The predominant form of ehrlichiosis that develops in equids in the United States is caused by *A phagocytophilum*.[61,62] Similar to the strain of *A phagocytophilum* that infects humans in the United States, the equine strain is transmitted by ixodid ticks; the primary vectors are believed to be *I scapularis* in the northeastern and north-central states and *I pacificus* in the northwest region.[62] Clinical signs of infection vary with age of the horse; the severity of the disease ranges from mild to severe. Common clinical signs develop over several days and include fever, lethargy, edema of the limbs, anorexia, and thrombocytopenia.[62,63] In horses with low numbers of platelets, petechial hemorrhages may develop. In rare instances, horses infected with *A phagocytophilum* may develop myocardial vasculitis and have premature ventricular contractions.[62] In addition, secondary infections may develop as a result of immunosuppression. The infection is self-limiting in most horses, although death can occur. In young animals, clinical signs may be milder than those observed in old horses.[62]

Ruminants—Infection with *E chaffeensis* has been detected in domestic goats in the United States, but clinical illness in these animals has not been reported. In goats from *E chaffeensis*-endemic areas, seropositivity has been identified, and the organism has been detected in blood samples via nucleic acid detection tests and bacteriologic culture.[64]

European strains of *A phagocytophilum* cause a febrile illness in sheep and cattle known as tick-borne fever.[65] The pathogen also infects a wide variety of wildlife in Europe, including rodents and cervids.[44,66,67] In the United States, seropositivity to *A phagocytophilum* has been demonstrated in some cattle, and experimentally infected animals seroconvert,[68,69] but clinical illness in cattle and sheep infected with US strains of *A phagocytophilum* has not been observed.[69]

Other domestic species—On the basis of clinical signs and cytologic examination of blood smears, ehrlichiosis caused by *E canis* or *A phagocytophilum* has occasionally been diagnosed in domestic cats.[70-72] In addition, infection with *A phagocytophilum* has been reported in a llama from California.[73] The llama exhibited clinical signs similar to those observed in horses in the United States that are infected with *A phagocytophilum*.

Diagnosis

In humans and animals, clinical diagnosis of ehrlichiosis is difficult because of the nonspecific nature of clinical signs, and laboratory assays are relied on for confirmation of suspected infections. Results of **polymerase chain reaction (PCR)** assays are useful to confirm active infection, but are not commonly available to most physicians or veterinarians.[74,75] The organism is difficult to isolate and must be grown in tissue culture.[75] Because morulae can sometimes be observed directly in infected neutrophils, cytologic examination of blood smears is another diagnostic tool; however, this evaluation lacks the sensitivity of serologic or PCR assays. Serologic tests (eg, an indirect immunofluorescence assay and enzyme immunoassay) are commercially available and are most frequently used for the diagnosis of ehrlichiosis.[75-77]

Results of serologic tests can assist a physician or veterinarian in making a diagnosis but must be interpreted with caution because of the clinical and epidemiologic features of the disease. Serologic test results for serum obtained during early illness may appear negative; therefore, whenever possible, paired samples of acute- and convalescent-phase sera (collected ≥ 3

weeks apart) should be assessed to confirm a diagnosis of ehrlichiosis.[78] In human medicine, a 4-fold change in antibody titer between such paired serum samples confirms ehrlichiosis, whereas a high titer detected in a single serum sample may indicate probable infection.[79] Antibody titers measured in single serum samples should be interpreted carefully because antibodies may persist for months after infection.[78] In serologic assays, cross-reactivity between various *Ehrlichia* and leukocytic *Anaplasma* spp is common; in areas where geographic distributions of the pathogens overlap, routine serologic tests may not be able to adequately differentiate among infecting species.[25,80] In these cases, additional evaluations (eg, western immunoblot analysis) may be useful to determine the infectious agent.[81]

Treatment

When there is a strong suspicion of ehrlichiosis on the basis of clinical and epidemiologic findings, antimicrobial treatment should be initiated immediately. Physicians and veterinarians should not wait for confirmation of infection via results of diagnostic tests because results of tests performed early in the course of the infection may be negative and delayed treatment may result in serious disease.[26,40,82] In humans and animals, tetracycline-class antimicrobials are the drugs of choice.[83,84] For the treatment of ehrlichiosis in humans, 100 mg of doxycycline is administered orally twice daily for 10 to 14 days.[82] In dogs, administration of 5 mg of doxycycline/kg (2.3 mg of doxycycline/lb) orally twice daily for 14 to 28 days has been shown to be efficacious in the treatment of infections with *E canis*, *E ewingii*, or *A phagocytophilum*, but this treatment appears to be less effective in eliminating infection with *E chaffeensis*.[59,84,85] In dogs, treatment of ehrlichiosis is most effective when antimicrobials are administered during the acute phase of infection because dogs may not be able to recover from the hematologic abnormalities associated with the chronic phase of infection. For treatment of ehrlichiosis in horses, it is recommended that oxytetracycline is administered (7 mg/kg [3.2 mg/lb], IV, q 24 h) for ≥ 8 days; in horses that are treated for ≤ 7 days, the condition may relapse.[62] In most affected humans and animals, defervescence occurs within 24 to 48 hours if effective treatment is administered; failure to rapidly respond to treatment suggests that the clinical diagnosis of ehrlichiosis was incorrect.

Prevention

Data from a study[86] in military working dogs have suggested that administration of antimicrobials may prevent ehrlichiosis infection; however, prophylactic use of such drugs in humans or animals with no clinical signs is not routinely recommended. At present, a vaccine to prevent ehrlichiosis is not available for use in humans or animals.

In the prevention of ehrlichiosis, efforts should focus on reducing the likelihood of tick bites. Prior to entering tick habitats, people can reduce their risk for tick bites by wearing clothing with long sleeves and long pants and by tucking the legs of pants into socks. Use of permethrin-treated clothing and sprays may also help.[87] In pets, the occurrence of tick bites may be reduced through use of topically applied acaricides or flea collars.[88,89] Persons and pets should be carefully checked for ticks after exposure to tick habitats. Strategies to reduce environmental densities of vector ticks through area-wide application of acaricides and control of tick habitats (eg, leaf litter and brush) may be employed, but these frequently have short-lived success.[90] Employing these techniques routinely in community-based programs may be more effective in controlling ticks than isolated control efforts.

Discussion

Although ehrlichiosis in humans is a nationally notifiable disease, reporting of cases of the disease in animals is not required. In the United States, it is likely that the disease is under-recognized and underreported because of the nonspecific nature of clinical signs. Ehrlichiosis can occur in a variety of domestic species; therefore, veterinarians and physicians should be alert for signs of the disease in humans and animals in disease-endemic areas and request appropriate diagnostic tests to aid in confirmation of infection.

References

1. Dumler JS, Barbet AF, Bekker CP, et al. Reorganization of genera in the families Rickettsiaceae and Anaplasmataceae in the order Rickettsiales: unification of some species of *Ehrlichia* with *Anaplasma*, *Cowdria* with *Ehrlichia* and *Ehrlichia* with *Neorickettsia*, descriptions of six new species combinations and designation of *Ehrlichia equi* and 'HGE agent' as subjective synonyms of *Ehrlichia phagocytophila*. *Int J Syst Evol Microbiol* 2001;51:2145–2165.
2. Rikihisa Y. The tribe *Ehrlichieae* and ehrlichial diseases. *Clin Microbiol Rev* 1991;4:286–308.
3. Lockhart JM, Davidson WR, Stallknecht DE, et al. Isolation of *Ehrlichia chaffeensis* from wild white-tailed deer (*Odocoileus virginianus*) confirms their role as natural reservoir hosts. *J Clin Microbiol* 1997;35:1681–1686.
4. Yabsley MJ, Varela AS, Tate CM, et al. *Ehrlichia ewingii* infection in white-tailed deer (*Odocoileus virginianus*). *Emerg Infect Dis* 2002;8:668–671.
5. Davidson WR, Lockhart JM, Stallknecht DE, et al. Susceptibility of red and gray foxes to infection by *Ehrlichia chaffeensis*. *J Wildl Dis* 1999;35:696–702.
6 Lockhart JM, Davidson WR, Stallknecht DE, et al. Natural history of *Ehrlichia chaffeensis* (Rickettsiales: Ehrlichieae) in the Piedmont physiographic province of Georgia. *J Parasitol* 1997;83: 887–894.
7. Comer JA, Nicholson WL, Paddock CD, et al. Detection of antibodies reactive with *Ehrlichia chaffeensis* in the raccoon. *J Wildl Dis* 2000;36:705–712.
8. Childs JE, Paddock CD. The ascendancy of *Amblyomma americanum* as a vector of pathogens affecting humans in the United States. *Annu Rev Entomol* 2003;48:307–337.
9. Wolf L, McPherson T, Harrison B, et al. Prevalence of *Ehrlichia ewingii* in *Amblyomma americanum* in North Carolina. *J Clin Microbiol* 2000;38:2795.
10. Walls JJ, Asanovich KM, Bakken JS, et al. Serologic evidence of a natural infection of white-tailed deer with the agent of human granulocytic ehrlichiosis in Wisconsin and Maryland. *Clin Diagn Lab Immunol* 1998;5:762–765.
11. Nicholson WL, Muir S, Sumner JW, et al. Serologic evidence of infection with *Ehrlichia* spp. in wild rodents (Muridae: Sigmodontinae) in the United States. *J Clin Microbiol* 1998;36: 695–700.
12. Telford SR III, Dawson JE, Katavolos P, et al. Perpetuation of the agent of human granulocytic ehrlichiosis in a deer tick-rodent cycle. *Proc Natl Acad Sci U S A* 1996;93:6209–6214.
13. Hodzic E, Fish D, Maretzki CM, et al. Acquisition and transmission of the agent of human granulocytic ehrlichiosis by *Ixodes scapularis* ticks. *J Clin Microbiol* 1998;36:3574–3578.

14. Foley JE, Barlough JE, Kimsey RB, et al. *Ehrlichia* spp. in cervids from California. *J Wildl Dis* 1998;34:731–737.

15. Foley JE, Kramer V, Weber D. Experimental infection of dusky-footed wood rats (*Neotoma fuscipes*) with *Ehrlichia phagocytophila* sensu lato. *J Wildl Dis* 2002;38:194–198.

16. Nicholson WL, Castro MB, Kramer VL, et al. Dusky-footed wood rats (*Neotoma fuscipes*) as reservoirs of granulocytic Ehrlichiae (Rickettsiales: Ehrlichieae) in northern California. *J Clin Microbiol* 1999;37:3323–3327.

17. Schultz SM, Nicholson WL, Comer JA, et al. Serologic evidence of infection with granulocytic ehrlichiae in black bears in Pennsylvania. *J Wildl Dis* 2002;38:47–53.

18. Foley JE, Foley P, Jecker M, et al. Granulocytic ehrlichiosis and tick infestation in mountain lions in California. *J Wildl Dis* 1999; 35:703–709.

19. Pusterla N, Chang CC, Chomel BB, et al. Serologic and molecular evidence of *Ehrlichia* spp. in coyotes in California. *J Wildl Dis* 2000;36:494–499.

20. Zeidner NS, Burkot TR, Massung R, et al. Transmission of the agent of human granulocytic ehrlichiosis by *Ixodes spinipalpis* ticks: evidence of an enzootic cycle of dual infection with *Borrelia burgdorferi* in Northern Colorado. *J Infect Dis* 2000;182:616–619.

21. Kramer VL, Randolph MP, Hui LT, et al. Detection of the agents of human ehrlichioses in Ixodid ticks from California. *Am J Trop Med Hyg* 1999;60:62–65.

22. Richter PJ Jr, Kimsey RB, Madigan JE, et al. *Ixodes pacificus* (Acari: Ixodidae) as a vector of *Ehrlichia equi* (Rickettsiales: Ehrlichieae). *J Med Entomol* 1996;33:1–5.

23. Parola P, Raoult D. Ticks and tickborne bacterial diseases in humans: an emerging infectious threat. *Clin Infect Dis* 2001;32: 897–928.

24. Eisen L, Eisen RJ, Lane RS. Seasonal activity patterns of *Ixodes pacificus* nymphs in relation to climatic conditions. *Med Vet Entomol* 2002;16:235–244.

25. Comer JA, Nicholson WL, Olson JG, et al. Serologic testing for human granulocytic ehrlichiosis at a national referral center. *J Clin Microbiol* 1999;37:558–564.

26. Eng TR, Harkess JR, Fishbein DB, et al. Epidemiologic, clinical, and laboratory findings of human ehrlichiosis in the United States, 1988. *JAMA* 1990;264:2251–2258.

27. Bakken JS, Krueth JK, Lund T, et al. Exposure to deer blood may be a cause of human granulocytic ehrlichiosis. *Clin Infect Dis* 1996;23:198.

28. Telford SR. Risk for acquiring human granulocytic ehrlichiosis: exposure to deer blood or deer ticks? *Clin Infect Dis* 1997;24: 531–533.

29. Parzy D, Davoust B, Bissuel G, et al. Human pathogenicity of *Ehrlichia canis*. *Lancet* 1991;337:1169.

30. McQuiston JH, Childs JE, Chamberland ME, et al. Transmission of tick-borne agents of disease by blood transfusion: a review of known and potential risks in the United States. *Transfusion* 2000;40:274–284.

31. Horowitz HW, Kilchevsky E, Haber S, et al. Perinatal transmission of the agent of human granulocytic ehrlichiosis. *N Engl J Med* 1998;339:375–378.

32. McQuiston JH, Paddock CD, Holman RC, et al. Human ehrlichioses in the United States. *Emerg Infect Dis* 1999;5:635–642.

33. Buller RS, Arens M, Hmiel SP, et al. *Ehrlichia ewingii*, a newly recognized agent of human ehrlichiosis. *N Engl J Med* 1999; 341:148–155.

34. Marshall GS, Jacobs RF, Schutze GE, et al. *Ehrlichia chaffeensis* seroprevalence among children in the southeast and south-central regions of the United States. *Arch Pediatr Adolesc Med* 2002; 156:166–170.

35. Hilton E, DeVoti J, Benach JL, et al. Seroprevalence and seroconversion for tickborne diseases in a high-risk population in the northeast United States. *Am J Med* 1999;106:404–409.

36. Bakken JS, Goellner P, Van Etten M, et al. Seroprevalence of human granulocytic ehrlichiosis among permanent residents of northwestern Wisconsin. *Clin Infect Dis* 1998;27:1491–1496.

37. Centers for Disease Control and Prevention. Notifiable diseases/deaths in selected cities weekly information. *MMWR Morb Mortal Wkly Rep* 2000;48:1183–1190.

38. Centers for Disease Control and Prevention. Notifiable diseases/deaths in selected cities weekly information. *MMWR Morb Mortal Wkly Rep* 2001;49:1167–1174.

39. Centers for Disease Control and Prevention. Notifiable diseases/deaths in selected cities weekly information. *MMWR Morb Mortal Wkly Rep* 2002;50:1169–1176.

40. Fishbein DB, Dawson JE, Robinson LE. Human ehrlichiosis in the United States, 1985 to 1990. *Ann Intern Med* 1994;120:736–743.

41. Bakken JS, Krueth J, Wilson-Nordskog C, et al. Clinical and laboratory characteristics of human granulocytic ehrlichiosis. *JAMA* 1996;275:199–205.

42. Ramsey AH, Belongia EA, Gale CM, et al. Outcomes of treated human granulocytic ehrlichiosis cases. *Emerg Infect Dis* 2002;8:398–401.

43. Paddock CD, Sumner JW, Shore GM, et al. Isolation and characterization of *Ehrlichia chaffeensis* strains from patients with fatal ehrlichiosis. *J Clin Microbiol* 1997;35:2496–2502.

44. Liz JS, Sumner JW, Pfister K, et al. PCR Detection and serological evidence of granulocytic ehrlichial infection in roe deer (*Capreolus capreolus*) and chamois (*Rupicapra rupicapra*). *J Clin Microbiol* 2002; 40:892–897.

45. Donatein A, Lestoquard F. Existence in Algerie d'une *Rickettsia* du chien. *Bull Soc Pathol Exot* 1935;29:418–419.

46. Walker JS, Rundquist JD, Taylor R, et al. Clinical and clinicopathologic findings in tropical canine pancytopenia. *J Am Vet Med Assoc* 1970;157:43–55.

47. Groves MG, Dennis GL, Amyx HL, et al. Transmission of *Ehrlichia canis* to dogs by ticks (*Rhipicephalus sanguineus*). *Am J Vet Res* 1975;36:937–940.

48. Woddy BJ, Hoskins JD. Ehrlichial diseases of dogs. *Vet Clin North Am Small Anim Pract* 1991;21:75–98.

49. Kuehn NF, Gaunt SD. Clinical and hematologic findings in canine ehrlichiosis. *J Am Vet Med Assoc* 1985;186:355–358.

50. McDade JE. Ehrlichiosis—a disease of animals and humans. *J Infect Dis* 1990;161:609–617.

51. Harrus S, Kass PH, Klement E, et al. Canine monocytic ehrlichiosis: a retrospective study of 100 cases, and an epidemiological investigation of prognostic indicators for the disease. *Vet Rec* 1997;141:360–363.

52. Waner T, Harrus S, Bark H, et al. Characterization of the subclinical phase of canine ehrlichiosis in experimentally infected beagle dogs. *Vet Parasitol* 1997;69:307–317.

53. Kelly PJ. Canine ehrlichioses: an update. *J S Afr Vet Assoc* 2000;71:77–86.

54. Perez M, Rikihisa Y, Wen B. *Ehrlichia canis*-like agent isolated from a man in Venezuela: antigenic and genetic characterization. *J Clin Microbiol* 1996;34:2133–2139.

55. Anderson BE, Greene CE, Jones DE, et al. *Ehrlichia ewingii* sp. nov, the etiologic agent of canine granulocytic ehrlichiosis. *Int J Syst Bacteriol* 1992;42:299–302.

56. Greig B, Asanovich KM, Armstrong PJ, et al. Geographic, clinical, serologic, and molecular evidence of granulocytic ehrlichiosis, a likely zoonotic disease, in Minnesota and Wisconsin dogs. *J Clin Microbiol* 1996;34:44–48.

57. Foley JE, Foley P, Madigan JE. Spatial distribution of seropositivity to the causative agent of granulocytic ehrlichiosis in dogs in California. *Am J Vet Res* 2001;62:1599–1605.

58. Kordick SK, Breitschwerdt EB, Hegarty BC, et al. Coinfection with multiple tick-borne pathogens in a Walker Hound kennel in North Carolina. *J Clin Microbiol* 1999;37:2631–2638.

59. Breitschwerdt EB, Hegarty BC, Hancock SI. Sequential evaluation of dogs naturally infected with *Ehrlichia canis*, *Ehrlichia chaffeensis*, *Ehrlichia equi*, *Ehrlichia ewingii*, or *Bartonella vinsonii*. *J Clin Microbiol* 1998;36:2645–2651.

60. Dawson JE, Biggie KL, Warner CK, et al. Polymerase chain reaction evidence of *Ehrlichia chaffeensis*, an etiologic agent of human ehrlichiosis, in dogs from southeast Virginia. *Am J Vet Res* 1996;57:1175–1179.

61. Madigan JE, Richter PJ Jr, Kimsey RB, et al. Transmission and passage in horses of the agent of human granulocytic ehrlichiosis. *J Infect Dis* 1995;172:1141–1144.

62. Madigan JE, Pusterla N. Ehrlichial diseases. *Vet Clin North Am Equine Pract* 2000;16:487–499.

63. Madigan JE, Gribble D. Equine ehrlichiosis in Northern California: 49 cases (1968–1981). *J Am Vet Med Assoc* 1987;190: 445–448.

64. Dugan VG, Little SE, Stallknecht DE, et al. Natural infection of domestic goats with *Ehrlichia chaffeensis*. *J Clin Microbiol* 2000;38:448–449.

65. Woldehiwet Z. Tick-borne fever: a review. *Vet Res Commun* 1983;6:163–175.

66. Petrovec M, Bidovec A, Sumner JW, et al. Infection with *Anaplasma phagocytophila* in cervids from Slovenia: evidence of two genotypic lineages. *Wien Klin Wochenschr* 2002;114:641–647.

67. Liz JS, Anderes L, Sumner JW, et al. PCR Detection of granulocytic ehrlichiae in *Ixodes ricinus* ticks and wild small mammals in western Switzerland. *J Clin Microbiol* 2000;38:1002–1007.

68. Magnerelli LA, Ijdo JW, Shermant BA, et al. Antibodies to granulocytic ehrlichiae in cattle from Connecticut. *J Med Microbiol* 2002;51:326–331.

69. Pusterla N, Anderson RJ, House JK, et al. Susceptibility of cattle to infection with *Ehrlichia equi* and the agent of human granulocytic ehrlichiosis. *J Am Vet Med Assoc* 2001;218:1160–1162.

70. Bouloy RP, Lappin MR, Holland CH, et al. Clinical ehrlichiosis in a cat. *J Am Vet Med Assoc* 1994;204:1475–1478.

71. Bjoersdorff A, Svendenius L, Owens JH, et al. Feline granulocytic ehrlichiosis—a report of a new clinical entity and characterization of the infectious agent. *J Small Anim Pract* 1999;40:20–24.

72. Breitschwerdt EB, Abrams-Ogg AC, Lappin MR, et al. Molecular evidence supporting *Ehrlichia canis*-like infection in cats. *J Vet Intern Med* 2002;16:642–649.

73. Barlough JE, Madigan JE, Turoff DR, et al. An *Ehrlichia* strain from a llama (*Lama glama*) and llama-associated ticks (*Ixodes pacificus*). *J Clin Microbiol* 1997;35:1005–1007.

74. Comer JA, Nicholson WL, Sumner JW, et al. Diagnosis of human ehrlichiosis by PCR assay of acute-phase serum. *J Clin Microbiol* 1999;37:31–34.

75. Walker DH, Task Force on Consensus Approach for Ehrlichiosis. Diagnosing human ehrlichioses: current status and recommendations. *ASM News* 2000;66:287–290.

76. Magnarelli LA, IJdo JW, Van Andel AE, et al. Reactivity of serum samples of dogs and horses tested by use of class-specific recombinant-based enzyme-linked immunosorbent assays for detection of granulocytic ehrlichiosis. *Am J Vet Res* 2001;62:1365–1369.

77. Belanger M, Sorenson HL, France MK, et al. Comparison of serological detection methods for diagnosis of *Ehrlichia canis* infections in dogs. *J Clin Microbiol* 2002;40:3506–3508.

78. Bakken JS, Haller I, Riddell D, et al. The serological response of patients infected with the agent of human granulocytic ehrlichiosis. *Clin Infect Dis* 2002;34:22–27.

79. Council of State and Territorial Epidemiologists. CSTE position statements 2000. Changes in the case definition for human ehrlichiosis, and addition of a new ehrlichiosis category as a condition placed under surveillance according to the National Public Health Surveillance System (NPHSS). Available at: www.cste.org/ps/2000/2000-id-03.htm. Accessed Sep 26, 2003.

80. Dumler JS, Asanovich KM, Bakken JS, et al. Serologic cross-reactions among *Ehrlichia equi*, *Ehrlichia phagocytophila*, and human granulocytic ehrlichiosis. *J Clin Microbiol* 1995;33:1098–1103.

81. Unver A, Felek S, Paddock CD, et al. Western blot analysis of sera reactive to human monocytic ehrlichiosis and human granulocytic ehrlichiosis agents. *J Clin Microbiol* 2001;39:3982–3986.

82. Bakken JS, Dumler JS. *Ehrlichia* species. In: Yu VL, Merigan TC Jr, Barriere SL, eds. *Antimicrobial therapy and vaccines*. Baltimore: The Williams & Wilkins Co, 1999;546–550.

83. Donovan BJ, Weber DJ, Rublein JC, et al. Treatment of tick-borne diseases. *Ann Pharmacother* 2002;36:1590–1597.

84. Breitschwerdt EB, Hegarty BC, Hancock SI. Doxycycline hyclate treatment of experimental canine ehrlichiosis followed by challenge inoculation with two *Ehrlichia canis* strains. *Antimicrob Agents Chemother* 1998;42:362–368.

85. Buhles WC Jr, Huxsoll DL, Ristic M. Tropical canine pancytopenia: clinical, hematologic, and serologic response of dogs to *Ehrlichia canis* infection, tetracycline therapy, and challenge inoculation. *J Infect Dis* 1974;130:357–367.

86. Davidson DE Jr, Dill GS Jr, Tingpalapong M, et al. Prophylactic and therapeutic use of tetracycline during an epizootic of ehrlichiosis among military dogs. *J Am Vet Med Assoc* 1978;172:697–700.

87. Yevich SJ, Sanchez JL, DeFraites RF, et al. Seroepidemiology of infections due to spotted fever group rickettsiae and *Ehrlichia* species in military personnel exposed in areas of the United States where such infections are endemic. *J Infect Dis* 1995;171:1266–1273.

88. Estrada-Peña A, Ascher F. Comparison of an amitraz-impregnated collar with topical administration of fipronil for prevention of experimental and natural infestations by the brown dog tick (*Rhipicephalus sanguineus*). *J Am Vet Med Assoc* 1999;214: 1799–1803.

89. Elfassy OJ, Goodman FW, Levy SA, et al. Efficacy of an amitraz-impregnated collar in preventing transmission of *Borrelia burgdorferi* by adult *Ixodes scapularis* to dogs. *J Am Vet Med Assoc* 2001;219:185–189.

90. Jongejan F, Uilenberg G. Ticks and control methods. *Rev Sci Tech* 1994;13:1201–1226.